

# *Evaluation of Interradicular Cortical Bone Thickness for Orthodontic Miniscrew Implant Placement Using Cone Beam Computed Tomography*

*Wahab R Jassim*

B.D.S. - Master Student, Oral & Maxillofacial Radiology

*Lamia H. Al-Nakib*

B.D.S., M.Sc. - Assistant Professor, Department of Oral Diagnosis, College of Dentistry, University of Baghdad

## **ABSTRACT**

**Background:** Two factors, safety and stability that clinicians should consider during miniscrew implant placement. Safety is involved to MD distance and stability is involved to bone thickness. No Iraqi studies had been evaluated bone thickness and mesiodistal distance related to mini-implant placement for orthodontic anchorage at age 18 -35 years

**The aim of study:** This study aimed to assess the three dimensional interradicular areas and the cortical bone thickness in Iraqi patients with Class I skeletal pattern and to determine the safe and suitable sites for orthodontic miniscrew implant by use the CBCT.

**Materials and Methods :** The sample of the present study include a total of 20 Iraqi arabic patients aged 18-35 years of both sexes (10 males and 10 females) attending the Porceka Center at al Hilla city for CBCT scan for different CBCT diagnostic purposes from the period between November 2014 to May 2015. Measurements were made from the mesial aspect of the first premolar to the mesial aspect of the second molar of mandible, at 2, 4, 6, 8, and 10 mm heights from the alveolar bone crest in each interradicular area.

**Results:** In males, the greatest buccal cortical thickness, buccolingual alveolar process width and mesiodistal distance were between the first and second molar at 10-mm height ( $3.8 \pm 0.92$  mm,  $15.7 \pm 1.33$  mm and  $4.7 \pm 1.01$  respectively). In females, the greatest buccal cortical thickness, buccolingual alveolar process width and mesiodistal distance were between the first and second molar at 10-mm height ( $2.7 \pm 0.16$  mm,  $13.8 \pm 1.59$  mm and  $6.1 \pm 0.91$  respectively). There was statistically significant sex difference in buccal cortical thickness, buccolingual alveolar process width and mesiodistal distance which were larger with males.

**Conclusion:** Cone Beam Computed Tomography is a precise tool for evaluation the interradicular area and buccal cortical bone thickness to select the most suitable position of orthodontic miniscrew insertion.

## **KEYWORDS**

Interradicular, Cortical Bone Thickness, Miniscrew Implant, CBCT.

## **CITE THIS ARTICLE**

Jassim W, Al-Nakib L. Evaluation of Interradicular Cortical Bone Thickness for Orthodontic Miniscrew Implant Placement Using Cone Beam Computed Tomography. *Iraqi Dent. J.* 2016; 38(1):28-35. <http://www.iraqidentaljournal.com>

## **INTRODUCTION**

Microscrew have many advantages, including effort less removal and placement, immediate cramping, minimize anatomical constraints due to their low and cost small size. Plenty reports have coped with various clinical cases, for example posterior or anterior teeth retraction, All teeth retraction, distalization, up righting or protraction of molars.<sup>(1,2)</sup>

Several sites had been proposed for the placement of miniscrews or microscrew implants. Most recommended sites were the midpalatine area; Interradicular spaces are generally the site of choice for mini implant placement for their ease of access, simplicity of procedure, and less traumatic placement<sup>(3)</sup>. The buccal interradicular area is commonly selected for miniscrew implant placement<sup>(4,5)</sup>.

This area is not only easy for miniscrew implant placement, but also allows relatively simple orthodontic mechanics<sup>(3,6)</sup>.

In craniofacial imaging the final advancing have made it possible to obtain (3D) acting with CBCT of the craniofacial structures.

CBCT was first enters to dentistry in the United States at the University of Loma Linda in 2000.<sup>(7)</sup>

The CBCT technique lets rapid data acquirement

more than CT. Evolved software is found for all unit, letting measuring and processing for image. With a versatile range of uses in the dental purposes, CBCT applications for diagnosis and treatment planning. Orthodontics has many advantages from CBCT.<sup>(8)</sup>

Compared with CT machines the advantages of CBCT are rather low cost and smaller size, 3D images of maxillofacial structures, easy of uses, rapid scans. Radiation dose levels achieved by CBCT is awarder to an all-mouth sequence, and less than (2 panoramic radiographs), adoption on the use setting.<sup>(9,10)</sup>

The final accuracy studies include CBCT image have shown that 3D measurements they are close to reality and more accurate than 2D measurements.<sup>(11,12)</sup>

Varied results of the accuracy of CBCT scan has been restudied on many machines. No statistically significant differences between anatomic truth and CBCT images found BY Some authors.<sup>(13)</sup>

Whereas others illustrated differences that, even though statistically different, were not considered clinically significant<sup>(14,15)</sup>.

CBCT which introduce clear 3D images with low voxel size. In recent years, has been broadly used in craniofacial diagnoses, orthodontics, and for accurate

surgical guidance for miniscrew placement. (16, 17).

In the present study, Cone Beam Computed Tomography was used as an aid in selection of precise position for miniscrew insertion.

## MATERIALS AND METHODS

Prospective study of CBCT scans for (20) Iraqi patients, with equal number of each gender (10males and 10 females), age ranged from (18-35) yrs. were analyzed. The sample collected from patient attending Porceka center in Al-Hilla City CBCT scan for different diagnostic purposes from November 2014 to May 2015.

### Criteria for the sample selection:

Full eruption of permanent dentition (except for third molars),no history of previous orthodontic treatment ,no missing teeth (exclude third molars),no severe craniofacial disorders, no severe periodontitis or periapical lesion, no large metal restoration, no severe crowding and spacing in posterior teeth and Class I skeletal pattern.

The examination was performed Cone Beam Computed tomography KODAK 9000C 3D machine (Trophy, France)

The patients were prepared for the exposure by asking them to remove any spectacles, jewelry, ear rings, and hearing aids.

Each patient was scanned on KODAK 9000C 3D machine (Trophy, France) which is in compliance with the requirements of the EEC (European Economic Community) and International Medical standards at 70kV and 10mA for 10.8 seconds for each quadrant of the jaw.

The CBCT images were formatted into standard DICOM and reconstructed into continuous slices at 1.0 mm thickness each. The CT image analysis for each image was conducted by Kodak 3D viewer, 2.2 version software, and oblique slicing images with sections of 1.0mm thickness were chosen for measurements.

The images were coincided in all the views (Cross-sectional,Panoramic,and Axial) Figure(1).

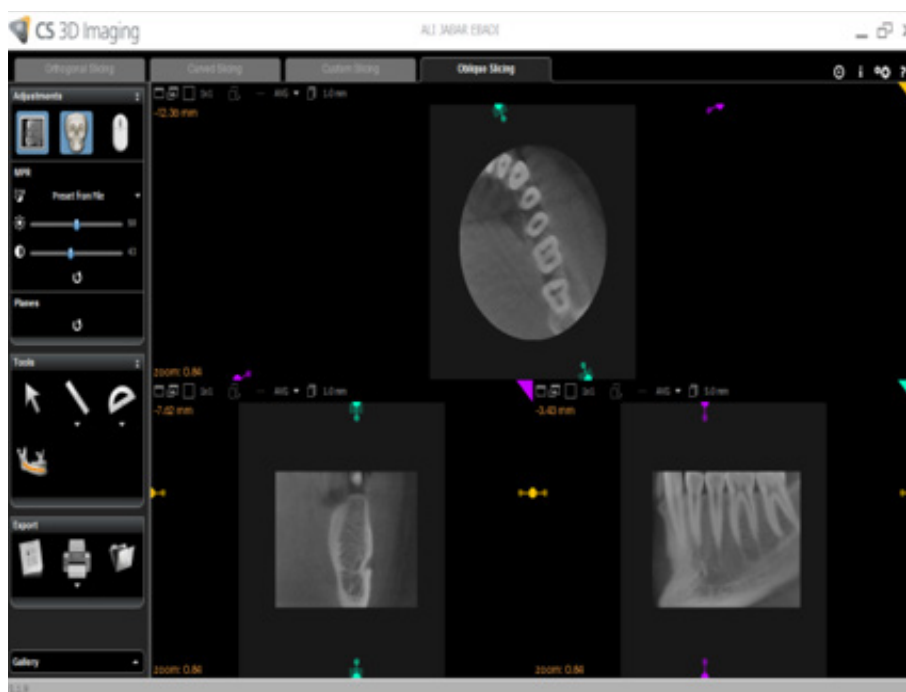

Figure1:CBCT image (panoramic, axial,and cross-sectional)

Before taking the linear measurement at various levels from the crest of alveolar bone. The cross-sectional images were perpendicular to the axial and panoramic planes. These images were used to measure mandibular Mesiodistal distance (MD), Buccolingual alveolar process width (BL) and Buccal cortical bone thickness (B-C).

**Mesiodistal distance (MD):** The distance between parallel lines tangent to the adjacent proximal root surfaces in the axial image Figure(2).

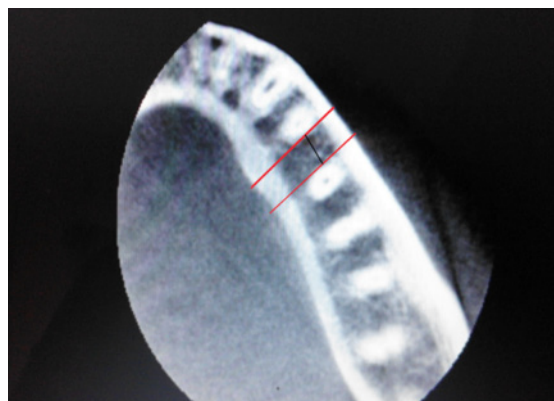
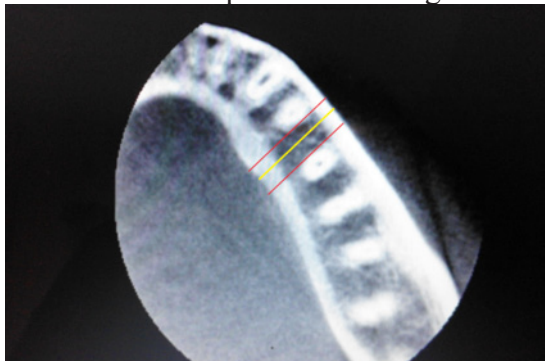


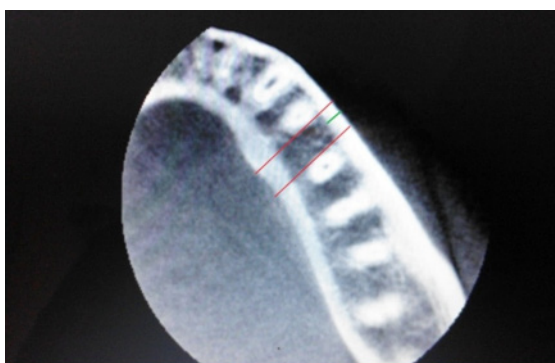
Figure2: Measurement of the interradicular distances

**Buccolingual alveolar process width (BL):** This width was measured at the center of the interradicular width between the tangent lines to the proximal root surfaces, from the outer most point on the buccal side to the outermost point on the lingual side Figure(3).



**Figure 3:** Measurement of the alveolar process width.

**Buccal cortical bone thickness (B-C):** The distance between the external and internal aspects of the buccal cortex midway between the tangent lines to the proximal root surfaces Figure(4).



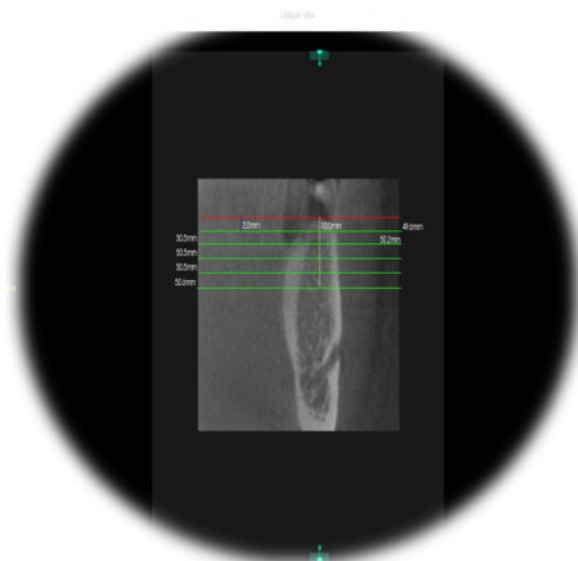
**Figure 4:** Measurement of the buccal cortical bone thickness

Procedure to measure CBT is as follows. Buccal CBT measurement was done at the interradicular space between 1<sup>st</sup> premolar-2<sup>nd</sup> premolar(4-5) and 2<sup>nd</sup> premolar-1<sup>st</sup> molar(5-6) and 1<sup>st</sup> molar-2<sup>nd</sup> molar(6-7) at 5 different levels, that is, (2,4,6,8,10) below the crest of alveolar bone. Each measurement was taken from the buccal alveolar plate. For this measurement, a reference horizontal line was drawn at the crest of alveolar bone parallel to CEJ and 5 horizontal measurements were taken parallel to this line at 5 different vertical levels.

To assess the safety of implant placement between these teeth, the mesiodistal interradicular distance and the alveolar process width (transverse distance from the buccal surface of the cortical bone to the lingual surface of the alveolar process) were measured.

For initial stability evaluation, cortical bone thickness was measured. First, sagittal images between the first premolar and the second premolar area that passed through the middle of the two teeth were constructed, then a horizontal line passing at the

crest of alveolar bone of the two teeth was drawn and then a horizontal lines was drawn at 5 heights from this transverse line 2, 4, 6, 8 and 10mm. Figure(5).



**Figure 5:** Sagittal images between the first premolar and the second premolar Sequential axial plane images at these 5 levels were constructed to measure the alveolar process width, mesiodistal distance (MD) and buccal cortical bone thickness at each axial plane at 2, 4, 6, 8 and 10 mm from the crest of alveolar bone.

For each patient, 45 measurements were measured and performed by one investigator. **Statistical Analysis:**

Data were translated into a computerized database structure. An expert statistical advice was sought for. Statistical analyses were computer assisted using SPSS version 21 (Statistical Package for Social Sciences). Frequency distribution for selected variables was done first.

The outcome measurements were normally distributed variables as tested by Kolmogorov-Semirnov test. Such variables are described by mean, standard deviation (SD) and standard error (SE). The statistical significance of differences in mean of a normally distributed variable between males and females was assessed by independent samples t-test.

The statistical significance of differences in mean of a normally distributed outcome variable measured more than once in the same subject (different vertical and AP positions) requires paired significance testing in a repeated measure general linear model analysis.

Cohen's d is a standardized measure of effect size for difference between 2 means, which can be compared across different variables and studies, since it has no unit of measurement. Cohen's  $d = (\text{mean1} - \text{mean2}) / \text{Pooled SD of the 2 groups}$ . Cohen's  $d < 0.3$  small effect, 0.3-0.7 (medium effect), while 0.8 and higher is a large effect.

A multiple linear regression model was used to study the net and independent effect of a set of explanatory variable on a quantitative outcome (dependent) variable.

**RESULTS**

Summary for the effect of sex, change in vertical level and change in (AP) position

**Buccal cortical bone thickness**

As shown in table (1), the net and independent effect of gender, vertical level and horizontal (AP) position were evaluated for their effect on buccal cortical bone thickness in a multiple linear regression model. The model was statistically significant and able to explain 0.74 of observed changes in the dependent (response or outcome) variable.

Being a male it is expected to significantly increase buccal cortical bone thickness by a mean of 0.47mm compared to female after adjusting (controlling) for vertical and horizontal level. For each 1mm increase in vertical level from the alveolar bon crest, the bucal cortical bone thickness is expected to significantly increase by a mean of 0.18mm after adjusting (controlling) for gender and horizontal level.

Compared to the most frontal position (4-5) after adjusting (controlling) for gender and vertical level, at the positions (5-6) and (6-7)is expected to significantly increase buccal cortical bone thickness by a mean of(0.24,1.02mm)respectively.

**Buccolingual alveolar process width**

As shown in table (2), the net and independent effect of gender , vertical level and horizontal (AP) position were evaluated for their effect on buccolingual alveolar process width in amultiple linear regression model. The model was statistically significant and able to explain 0.75 of observed changes in the dependent (response or outcome) variable.

Being a male is expected to significantly increase buccolingual alveolar process width by a mean of 2.08mm compared to female after adjusting (controlling) for vertical and horizontal level.

For each 1mm increase in vertical level from the alveolar bon crest, the buccolingual alveolar process width is expected to significantly increase by a mean of 0.48mmafter adjusting (controlling) for gender and horizontal level.

Compared to the most frontal position (4-5)after adjusting (controlling) for gender and vertical level, at the positions (5-6) and (6-7)is expected to significantly increase buccolingual alveolar process width by a mean of (1.07,3.27mm) respectively.

**Mesiodistal (inter-radicular) distance (MD)**

As shown in table (3), the net and independent effect of sex, vertical level and horizontal (AP) position were evaluated for their effect on mesiodistal (inter-radicular) distance (MD) in a multiple linear regression model. The model was statistically significant and able to explain (0.69) of observed changes in the dependent (response or outcome) variable.

Being a male is expected to significantly decrease mesiodistal (inter-radicular ) distance (MD)by a mean of (-0.34)mm compared to female after adjusting (controlling) for vertical and horizontal level.

For each 1mm increase in vertical level from the alveolar bone crest, the mesiodistal (inter-radicular) distance (MD) is expected to significantly increase by a mean of (0.21) mm after adjusting (controlling) for gender and horizontal level.

Compared to the most frontal position (4-5)after adjusting (controlling) for sex and vertical level, at the positions (5-6) is expected to significantly decrease mesiodistal (inter-radicular ) distance (MD)by a mean of (-0.41mm),and (6-7)is expected to significantly increase mesiodistal (inter-radicular ) distance (MD) by a mean of (1.25)mm.

**Table 1: Effect of gender, vertical and (AP) level on buccal cortical bone thickness**

<i>Cortical thickness (mm)</i>	<i>Partial regression Coefficient</i>	<i>P</i>	<i>Standardized Coefficients</i>
(Constant)	0.09	0.21[NS]	
male compared to femal	0.47	<0.001	0.285
(5-6)compared to(4-5)	0.24	<0.001	0.136
(6-7)compared to(4-5)	1.02	<0.001	0.584
Level(distance from crest inmm)	0.18	<0.001	0.615

**R2=0.74**  
**P (Model) <0.001**

**Table 2: Effect of Sex, vertical and (AP) level on buccolingual alveolar process width**

<i>Buccolingual alveolar process width (mm)</i>	<i>Partial regression Coefficient</i>	<i>P</i>	<i>Standardized Coefficients</i>
(Constant)	5.43	<0.001	
male compared to femal	2.08	<0.001	0.411
(5-6)compared to(4-5)	1.07	<0.001	0.200
(6-7)compared to(4-5)	3.27	<0.001	0.609
Level(distance from crest in mm)	0.48	<0.001	0.538

**R2=0.75**  
**P (Model) <0.001**

**Table 3: Effect of sex, vertical and (AP) level on mesiodistal (inter-radicular ) distance (MD)**

<i>Mesio-distal (inter-radicular)distance in mm</i>	<i>Partial regression Coefficient</i>	<i>P</i>	<i>Standardized Coefficients</i>
(Constant)	2.02	<0.001	
male compared tofemal	-0.34	<0.001	-0.149
(5-6)compared to(4-5)	-0.41	<0.001	-0.170
(6-7)compared to(4-5)	1.25	<0.001	0.521
Level (distance from crest in mm)	0.21	<0.001	0.529

**R2=0.69**  
**P (Model) <0.001**

## DISCUSSION

Computed Tomography permits the dental professional to visualize what the conventional radiographs never showed. The visualization of labial/buccal and lingual plates was not possible due to image superimposition of conventional radiographs<sup>(18)</sup>. CT gives accurate and reliable measurements of mandibular cortical bone thickness<sup>(19)</sup>.

In the present study , CBCT was used since the effective dose of radiation for CBCT scans is much lower than for medical Computed Tomography scans and is restricted to maxillofacial area<sup>(20)</sup>.

The interradicular spaces were the areas of interest in this study, since they were generally the site of choice for mini implant placement for their ease of access, simplicity of procedure, and less traumatic placement.

The choice of current study for the mandible as the sites for measuring cross-sectional bony thickness was made for practical and application based issues.

In the mandible, the space between the 2nd premolar and 1st molar is the preferred site for anterior tooth retraction, and the space between the 1st premolar and 2nd premolar is often used for the mesial movement of molars. In addition, the mandibular buccal molar areas can be used for an TAD to intrude the molars<sup>(21)</sup>.

Therefore, determination of the cortical bone

thickness of the mandibular molar region will be helpful for the selection of TAD placement sites. In the present study the side with full set of dentition was studied for measurements to exclude the effect of extraction on bone thickness. This was decided because that it was concluded that no significant difference existed in thickness of cortical bone between the sides of the mandible<sup>(19, 22)</sup>.

### Buccal cortical bone thickness

According to **Dalstra and Melsen(2004)**<sup>(23)</sup>, a microimplant should have enough initial stability if peri-implant bone tissue has more than 1mm of cortical bone thickness. **Motoyoshi et al., (2007)**<sup>(24)</sup> stated that the mini-implant site should have a cortical bone thickness of at least 1.0 mm. In present study, more than 1mm cortical bone thickness in all locations except at 2 mm from the crest of alveolar bone at the position between first and second premolars which is not a suggested area for mini-implant placement. Therefore, if all other factors of initial stability are satisfied, the range of mean cortical bone thickness in this study should provide sufficient initial stability. In this study a statistically significant difference between males and females in alveolar cortical bone thickness was found. The cortical bone thickness were greater in males than in females .These results is agreed with those found by **Kang et al,2007**, **Ono et al.,2008** and **Fayed et al.,2010**<sup>(25,26,5)</sup>who observed that the cortical bone thickness is more in males than in females.

The sex difference in cortical bone thickness recorded in the current study might be expected because males have larger bite forces and masticatory muscles than females <sup>(27, 28)</sup> .

Males have larger masticatory muscles and greater maximum biting forces than females <sup>(28, 29)</sup>. Although sex differences in diet have been reported maximum biting forces rarely occur in daily mastication <sup>(30, 31)</sup>. The forces required to masticate modern diets is far below the maximum biting force <sup>(32)</sup>. The similarity in cortical bone thickness indicates that the strains associated with daily masticatory forces are more important in determining group differences than maximum bite forces or muscle mass.

On the other hand, other studies reported no sex differences in cortical bone thickness which are inconsistent with the present study. This lack of sex difference in cortical bone thickness has been previously demonstrated by **Deguchi et al., 2006; Ono et al., 2008; Park et al., 2008; Choi et al., 2009; Farnsworth et al., 2011** <sup>(33,26,34,35,6)</sup> .

Another interesting finding was that gradual increase in the alveolar cortical bone thickness at different distances from the alveolar crest was found.

These results is agreed with those found by **Deguchi et al., 2006** <sup>(33)</sup> and **Ono et al., 2008** <sup>(26)</sup>. who observed that the cortical bone thickness tends to be thicker at greater heights and thinner at shallow levels.

In a study conducted by **Park and Cho 2009** <sup>(34)</sup>, the thickness of mandibular cortical bone, increasing from the CEJ toward the apex which are consistent with the present study.

**Moslemzade et al., 2014** <sup>(35)</sup> found similar results in their morphometric study; they reported buccal cortical bone increases in thickness as the distance of the measurement points from the alveolar crest increases.

However **Ono et al., 2008** <sup>(26)</sup> showed that the greater the height, the thicker the cortical bone tended to be which are consistent with the present study

In the current study , it was revealed that cortical bone thickness increased from anterior to posterior on the buccal side of the mandible, these findings are consistent with studies by **Farnsworth et al., (2011), Horner et al., (2012)** and **Moslemzade et al., (2014)** <sup>(6,36,35)</sup>. The pattern can be explained by masticatory force distribution within the mandible. The force developed during biting increases from anterior teeth to molars <sup>(37, 38)</sup>. Therefore, bone in the molar areas is subjected to the higher levels of stress and strains, necessitating more bony adaptation than in the anterior region. The thicker cortical bone in

the posterior mandible makes it well suited for MSI placement.

In a study by **Baumgaertel and Hans (2009)** <sup>(4)</sup>, cortical bone thickness in the buccal area for the placement of mini-implants was evaluated on 30 dry skulls using CBCT technique. The results showed a higher cortical bone thickness in posterior areas and the thickness increased by moving away from the bone crest, consistent with the results of the present study.

These results are agreed with those found by **Baumgartel and Hans, 2009** <sup>(4)</sup> who found a buccal cortical bone thinnest in the anterior sextants of both jaws and a progressive increase toward the posterior region. **Farnsworth et al., 2011** <sup>(6)</sup> showed a cortical bone thickness decrease from posterior to anterior region. The current study suggests that the posterior area may contain denser and thicker cortical bone. This pattern might be explained by the higher functional demands placed on the posterior teeth <sup>(39, 40)</sup>.

#### **Buccolingual alveolar process width**

Generally males are bigger than females in most dimensions <sup>(41)</sup>, they have thicker alveolar ridge than females due to greater medullary bone in addition to larger teeth males have in comparison to females in all dimensions <sup>(42)</sup>. The difference in tooth size and body size may explain the differences in alveolar ridge width. **Swasty et al., 2011** <sup>(43)</sup> reported that males have thicker ridges than females only in the premolar and canine regions of the upper third of the mandible which are inconsistent with the present study. However, their study was based on a wide age-range (10-65 years old) and the number of males and females were not indicated.

The results of current study showed a consistent increase in the buccolingual thickness in most of the studied sites in the mandible when moving apically and posteriorly, **Fayed et al., (2010)** is in agreement with the results revealed by the present study.

#### **REFERENCES**

1. Park HS. The use of micro-implant as orthodontic anchorage. Seoul, Korea: Nare; 2001.
2. Park HS, Bae SM, Kyung HM, Sung JH. Micro-implant anchorage fortreatment of skeletal ClassIb alveolar protrusion. J ClinOrthod2001; 35: 417-22.
3. Chaimanee P, Suzuki B, Suzuki EY. "Safe zones" for miniscrew implant placement in different dentoskeletal patterns. Angle Orthod2011;81(3):397-403.
4. Baumgaertel S, Hans MG. Buccal cortical bone thickness for mini-implant placement. Am J OrthodDentofacialOrthop 2009;136(2):230-5.
5. Fayed MM, Pazera P, Katsaros C. Optimal sites for orthodontic mini-implant placement assessed by cone beam computed tomography. Angle Orthod2010;80(5):939-51.
6. Farnsworth D, Rossouw PE, Ceen RF, Buschang PH. Cortical

- bone thickness at common miniscrew implant placement sites. *Am J OrthodDentofacialOrthop*2011;139(4):495-503.
7. Mah J, Hatcher D. Three-dimensional craniofacial imaging. *Am J OrthodDentofacialOrthop*2004 Sep;126(3):308-9.
  8. Baumgaertel S, Palomo JM, Palomo L, Hans MG. Reliability and accuracy of cone-beam computed tomography dental measurements. *Am J OrthodDentofacialOrthop*2009 Jul;136(1):19-25.
  9. Mah JK, Danforth RA, Bumann A, Hatcher D. Radiation absorbed in maxillofacial imaging with a new dental computed tomography device. *Oral Surg Oral Med Oral Pathol Oral RadiolEndod*2003 Oct;96(4):508-13.
  10. Ludlow JB, Davies-Ludlow LE, Brooks SL, Howerton WB. Dosimetry of 3 CBCT devices for oral and maxillofacial radiology: CB Mercuray, NewTom 3G and i-CAT. *DentomaxillofacRadiol*2006 Jul;35(4):219-26.
  11. Lascala CA, Panella J, Marques MM. Analysis of the accuracy of linear measurements obtained by cone beam computed tomography (CBCT-NewTom). *DentomaxillofacRadiol* 2004 Sep;33(5):291-4.
  12. Hilgers ML, Scarfe WC, Scheetz JP, Farman AG. Accuracy of linear temporomandibular joint measurements with cone beam computed tomography and digital cephalometric radiography. *Am J OrthodDentofacialOrthop*2005 Dec; 128(6):803-11.
  13. Yamamoto K, Ueno K, Seo K, Shinohara D. Development of dento-maxillofacial cone beam X-ray computed tomography system. *OrthodCraniofac Res* 2003;6 Suppl 1:160-2.
  14. Mozzo P, Procacci C, Tacconi A, Martini PT, Andreis IA. A new volumetric CT machine for dental imaging based on the cone-beam technique: preliminary results. *EurRadiol*1998;8(9):1558-64.
  15. Marmulla R, Wortche R, Muhling J, Hassfeld S. Geometric accuracy of the NewTom 9000 Cone Beam CT. *DentomaxillofacRadiol* 2005 Jan;34(1):28-31.
  16. Huang J, Buman A, Mah J. The cutting edge: threedimensional radiographic analysis in orthodontics. *J ClinOrthod*2005;39:421-8.
  17. Kim SH, Choi YS, Hwang EH, Chung KR, Kook YA, Nelson G. Surgical positioning of orthodontic mini-implants with guides fabricated on models replicated with cone-beam computed tomography. *Am J OrthodDentofacialOrthop* 2007;131, S82-89.
  18. Garib D. G., Yatabe M.S., Ozawa T.O., Filho S. Alveolar bone morphology under the perspective of the computed tomography: Defining the biological limits of tooth movement. *Dental Press J. Orthod.* 2010; 15(5): 192-205.
  19. Atson C. S., Sandra Q.U., Murillo L. M., Laila A. M., Márcio M. Direct and tomographic dimensional analysis of the inter-radicular distance and thickness of the vestibular cortical bone in the parasymphiseal region of adult human mandibles. *British Journal of Oral and Maxillofacial Surgery* 2012; 50(4):350-355.
  20. Scarfe WC, Farman AG. What is cone-beam CT and how does it work?. *Dent Clin North Am*2008; 52(4):707-30.
  21. Kim J, Park Y. Evaluation of mandibular cortical bone thickness for placement of temporary anchorage devices (TADs). *Korean J Orthod*2012; 42(3):110-117.
  22. Hu KS, Kang MK, Kim TW, Kim KH, Kim HJ. Relationships between dental roots and surrounding tissue for orthodontic mini screw installation. *Angle Orthod.* 2009 Jan;79(1):37-45.
  23. Dalstra M CP, Melsen B. Load transfer of miniscrews for orthodontic anchorage. *J Orthod* 2004;1:53-62.
  24. Motoyoshi M, Yoshida T, Ono A, Shimizu N. Effect of corticalbone thickness and implant placement torque on stability oforthodontic mini-implants. *Int J Oral Maxillofac Implants*2007;22:779e84.
  25. Kang S, Lee SJ, Ahn SJ, Heo MS, Kim TW. Bone thickness of the palate for orthodontic mini-implant anchorage in adults. *Am J OrthodDentofacialOrthop* 2007Apr:131(supp 14):s74-s81.
  26. Ono A, Motoyoshi M, Shimizu N. Cortical bone thickness in the buccal posterior region for orthodontic mini-implants. *Int J Oral and Max Surg*2008;37:334-40.
  27. Braun S, Hnat WP, Freudenthaler JW, Marcotte MR, Hönigle K, Johnson BE. A study of maximum bite force during growth and development. *Angle Orthod.* 1996;66:261-4.
  28. Usui T, Uematsu S, Kanegae H, Morimoto T, Kurihara S. Change in maximum occlusal force in association with maxillofacial growth. *OrthodCraniofac Res.* 2007;10:226-34.
  29. Koc D, Dogan A, Bek B. Bite Force and Influential Factors on Bite Force Measurements: A Literature Review. *Eur J Dent.* 2010;4:223-32.
  30. Bates CJ, Prentice A, Finch S. Gender differences in food and nutrient intakes and status indices from the National Diet and Nutrition Survey of people aged 65 years and over. *Eur J ClinNutr.* 1999;53:694-9.
  31. Wardle J, Haase A, Steptoe A, Nillapun M, Jonwutiwes K, Bellisie F. Gender differences in food choice: The contribution of health beliefs and dieting. *Ann Behav Med.* 2004;27:107-16.
  32. Scully C. *Oxford Handbook of Applied Dental Sciences.* Oxford University Press; 2002.
  33. Deguchi T, Nasu M, Murakami K, Yabuuchi T, Kamioka H, Takano-Yamamoto T. Quantitative evaluation of cortical bone thickness with computed tomographic scanning for orthodontic implants. *Am J OrthodDentofacialOrthop*2006;129:721.e7-12.
  34. Park J, Cho HJ. Three-dimensional evaluation of interradicular spaces and cortical bone thickness for the placement and initial stability of microimplants in adults. *Am J OrthodDentofacialOrthop*2009;136:314.e1-314.e12.
  35. Moslemzade S, Kananizadeh Y, Nourizadeh A, Sohrabi A, Panjinoosh M, Shafiee E. Evaluation of cortical bone thickness of mandible with cone beam computed tomography for orthodontic mini implant installation. *2014 Jul;2(2):52.*
  36. Horner KA, Behrents RG, Kim KB, Buschang PH. Cortical boneandridgethicknessofhyperdivergentandhypodivergent adults. *AmJOrthodDentofacialOrthop.*2012;142:170-8.
  37. Daegling DJ, Hotzman JL. Functional significance of cortical bone distribution in anthropoid mandibles: an in vitro assessment of bone strain under combined loads. *Am J PhysAnthropol.* 2003;122:38-50.
  38. Ichim I, Kieser JA, Swain MV. Functional significance of strain distribution in the human mandible under masticatory load: numerical predictions. *Arch Oral Biol.* 2007;52:465-73.
  39. Throckmorton GS, Dean JS. The relationship between jaw-muscle mechanical advantage and activity levels during isometric bites in humans. *Arch Oral Biol.* 1994;39:429-37.
  40. Ferrario VF, Sforza C, Serrao G, Dellavia C, Tartaglia GM. Single tooth bite forces in healthy young adults. *J Oral*

Rehabil. 2004;31:18-22.

41. Ogden CL, Fryar CD, Carroll MD, Flegal KM. Mean body weight, height, and body mass index, United States 1960-2002. *Adv Data*. 2004;347:1-17.
42. Schwartz GT, Dean MC. Sexual dimorphism in modern human permanent teeth. *Am J PhysAnthropol*. 2005;128:312-7.
43. Swasty D, Lee J, Huang JC, Maki K, Gansky SA, Hatcher D, Miller, AJ. Cross-sectional human mandibular morphology as assessed in vivo by cone-beam computed tomography in patients with different vertical facial dimensions. *Am J OrthodDentofacialOrthop*2011;139:e377-e89.